

Pectus excavatum: history, hypotheses and treatment options

Christoph Brochhausen^{a,*}, Salmai Turial^{b,†}, Felix K.P. Müller^{a,†}, Volker H. Schmitt^a, Wiltrud Coerdts^a,
Jean-Marie Wihlm^c, Felix Schier^b and C. James Kirkpatrick^a

^a REPAIRlab, Institute of Pathology, University Medical Centre Mainz, Mainz, Germany

^b Department of Paediatric Surgery, University Medical Centre Mainz, Mainz, Germany

^c Department of Thoracic Surgery, NHC, Hôpitaux Universitaires, Strasbourg, France

* Corresponding author: REPAIR Laboratory, Institute of Pathology, University Medical Centre Mainz, Langenbeckstraße 1, 55131 Mainz, Germany.
Tel: +49-6131-177307; fax: +49-6131-17477307; e-mail: brochhausen@pathologie.klinik.uni-mainz.de (C. Brochhausen).

Received 21 March 2011; received in revised form 10 January 2012; accepted 18 January 2012

Abstract

Pectus excavatum and pectus carinatum represent the most frequent chest wall deformations. However, the pathogenesis is still poorly understood and research results remain inconsistent. To focus on the recent state of knowledge, we summarize and critically discuss the pathological concepts based on the history of these entities, beginning with the first description in the sixteenth century. Based on the early clinical descriptions, we review and discuss the different pathogenetic hypotheses. To open new perspectives for the potential pathomechanisms, the embryonic and foetal development of the ribs and the sternum is highlighted following the understanding that the origin of these deformities is given by the disruption in the maturation of the parasternal region. In the second, different therapeutic techniques are highlighted and based on the pathogenetic hypotheses and the embryological knowledge potential new biomaterial-based perspectives with interesting insights for tissue engineering-based treatment options are presented.

Keywords: Pectus excavatum • Funnel chest • History • Hypotheses • Development • Chest wall deformity

INTRODUCTION

Congenital chest wall deformities can be classified into rare entities such as the cleft sternum, pentalogy of Cantrell, asphyxiating thoracic dystrophy (Jeune syndrome), Poland syndrome and spondylothoracic dysplasia (Jarcho–Levin syndrome), which represent ~3–4% of all cases, with pectus excavatum (PE) and pectus carinatum (PC) representing 95–97% of all chest wall deformities. PE represents a depression in the anterior chest wall as a result of dorsal deviation of the sternum and the third to seventh rib or costal cartilage, and is the most common chest wall deformity, representing 90% of all cases. Depending on the severity of PE, deviations of thoracic organs and spine deformities are known. Although PE in most instances has little or no influence on the function of the inner organs, the cosmetic appearance of the patients leads to psychological impairment which requires therapy. The most established treatment options are surgical interventions. There are a variety of operation methods which have been developed. Regarding the formal pathogenesis of PE, several hypotheses exist, although the underlying pathomechanisms are not at all clearly understood. Furthermore, questions arise about the role of developmental processes in the formation of PE.

The present report summarizes the pathophysiological hypotheses based on an historical overview of the description of PE and highlights the development of the sterno-clavicular joint.

[†]Both authors contributed equally to this work.

[†]This work contains material from the medical thesis of Felix K.P. Müller.

Summarizing the different therapeutical techniques, we highlight potential new perspectives.

THE HISTORY OF PECTUS EXCAVATUM DESCRIPTION

The first description of a funnel-formed chest wall came from Bauhinus [1] in the sixteenth century. Another documented description of an appearance of the thorax could be found in 1860 by Woillez [2]. In 1863, von Luschka [3] reported about a 6-cm deep depression in the thorax wall of a 24-year-old man. In 1870, Eggel [4] published the first comprehensive case report of a patient with a funnel-formed thorax depression calling it a 'miraculum naturae'. He assumed that the reason for the deformity would be a weakness and an abnormal flexibility of the sternum caused by nutritional disturbance or by developmental failure. Individual case reports followed by Williams [5], Fleisch [6] and Hagmann [7]. The latter believed that overgrowth of the ribs causes the depression of the chest. In contrast, Langer and Zuckerkandel [8] favoured the hypothesis of a developmental failure, taking place *in utero*, in which the lower jaw of the foetus is responsible for the deformity by pushing on the sternum as a result of too high intrauterine pressure. Regarding surgical correction, Meyer performed the first operation of PE in 1911 with the removal of the rib cartilage [9]. He also analysed the removed cartilage microscopically and identified an unspecific degeneration. However, he did not link the histological findings with the pathogenesis of PE.

EPIDEMIOLOGY AND CLINICAL PICTURE OF PECTUS EXCAVATUM

The incidence of PE has a ratio between 0.1 and 0.8 per 100 persons [10]. Interestingly, males are more often affected, with a gender distribution between 2:1 and 9:1 [11]. Even if PE occurs sporadically, a genetic predisposition seems likely, since a positive family history could be found in up to 43% of PE cases [12, 13]. However, a specific genetic defect has not yet been found. Most cases of PE could be noted clinically within the first year of life, but primary occurrence in puberty is also described. Mostly, chest wall deformities represent a single anomaly, but they could also be one manifestation of various genetic disorders. In this context, Kotzot and Schwabegger [14] gave a comprehensive overview about all syndromes associated with chest wall deformities. Colombani [15] mentioned that only <1% of patients with PE have an underlying connective tissue disorder.

Clinically, PE is associated with a typical posture [14]: thin, tall patients with a pot-belly and forward-drifted shoulders, which could lead to permanent scoliosis [15, 16]. The depression of the sternum can displace the heart and reduce the lung volume [13, 17]. As a result of the anatomical changes, chest pain [12, 13, 15], fatigue [15], dyspnoea on exertion [12, 13, 15, 18], respiratory infections [13], asthma symptoms [13], palpitations [12] or heart murmurs could occur [13]. Several cases with mitral valve prolapse [13, 15, 19], mitral valve regurgitation and ventricle compression could be found [15, 17, 19]. For the latter, Coln *et al.* [19] demonstrated that 95% of 123 patients had cardiac compression. Even a single case report of syncopal symptoms has been reported. The pulmonary and cardiovascular functions of patients with PE deformities were analysed in many investigations and have revealed measurable deficiencies [12]. Fonkalsrud *et al.* [13] reported that the symptoms of many untreated PE patients become progressively worse with age and he recommended an operational intervention for both young and adult patients.

In contrast to these descriptions of more or less severe clinical signs, symptoms affecting daily life activities are either rare [20]. Therefore, some authors described the indication for a PE correction to be primarily cosmetic.

Numerous clinical studies described an improvement of pulmonary and/or cardiovascular symptoms and improvement in the subjective well-being after surgical correction [9, 13, 16–18]. Malek *et al.* [18, 21] concluded that an operative intervention improves cardiovascular but not pulmonary function. Guntheroth [22] and Spiers as well as Johnson *et al.* [23] re-evaluated the source data of Malek's meta-analyses and stated that due to relevant methodological deficits, these data failed to demonstrate any improvement of cardiac function [23]. In this context, Aronson *et al.* [24] could not show an improvement in lung function parameters after Nuss procedure. Numerous authors highlight the psychological factors due to the physiognomic features of the chest wall deformity [15]. The deformities are thought to cause relevant social discrimination, especially during adolescence, leading to the socio-psychologic problems [15]. A multicentre study demonstrated that the surgical repair of PE patients improves these socio-psychologic problems [25].

HYPOTHESES AND PATHOPHYSIOLOGICAL CONCEPTS

There exist several hypotheses regarding its pathogenesis. Bauhinus [1] gave the first pathophysiological hypothesis,

mentioning a hypertension of the diaphragm during embryonic development as the pathophysiologic factor. At the end of the nineteenth and beginning of the twentieth century, one leading opinion on pathogenesis was intrauterine pressure on the sternum through an abnormal position of the embryo [5, 8]. An alternative idea invoked acquired damage caused by a permanent mechanical stress through an extreme position, given by cobblers. Further hypotheses highlighted other diseases such as syphilis or rickets as the reason for PE. In contrast, Brown [26] published in 1939 his observations of a thickened ligamentum substernale, which should lead to a retraction of the sternum. A further hypothesis favoured an imbalance between the anterior and posterior musculature of the muscle fibres of the anterior part of the diaphragm with a movement of the xiphoid and sternum backwards.

Today's leading hypotheses focused on a defective metabolism in the sternocostal cartilage, resulting in a biomechanical weakness and an overgrowth of the sternocostal cartilage [27]. The latter hypothesis was proven by Fokin *et al.* [28], who found a variable cellularity and matrix disorganization in the cartilage of PE patients. However, Nakaoka *et al.* [29] demonstrated that the costal cartilage on the side of the deepest impression is no longer compared with that of the contralateral side.

A systematic analysis of the histological changes in the sternocostal cartilage of PE patients revealed a premature ageing of the cartilage [30]. Regarding the cause for an inadequate degradation, an ultrastructural and biochemical study demonstrated abnormalities in the content of trace elements in the costal cartilage from PE patients, namely decreased levels of zinc and increased levels of magnesium and calcium [31], who demonstrated that the lack of zinc in the diet results in a lower metabolic activity of chondrocytes. Feng *et al.* [32] were able to demonstrate the deficit of the biomechanical qualities in the cartilage from PE patients. These findings give interesting insights in the correlation of metabolic lesions and mechanical properties of the cartilage in PE.

Finally, two main hypotheses for the pathogenesis of PE exist: a developmental disorder or cartilage overgrowth. In the latter, overgrowth caused by maturation disturbances is discussed. Taking these two aspects together, the potential relationship to the development of the ribs and the sternocostal joint is of interest. A summary of the pathophysiological concepts is given in Fig. 1.

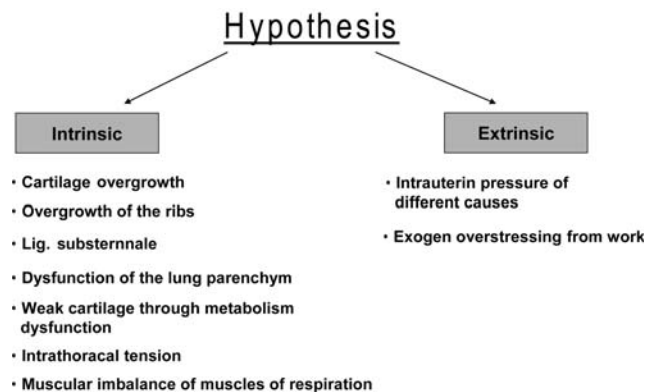


Figure 1: Schematic depiction of the different hypotheses about intrinsic and extrinsic pathogenetic factors.

EMBRYONIC DEVELOPMENT OF THE RIBS, STERNUM AND STERNOCOSTAL JUNCTIONS

The trunk develops from the mesoderm. These cells undergo an epithelial–mesenchymal transition (EMT), creating mesenchymal cells, which are arranged on each side of the chorda dorsalis and result in the paraxial mesoderm. The mesenchymal cells condense to cell clusters and hence lead to the segmental-oriented somites. During the fourth week, the somites differentiate in the ventromedial sclerotome and the dorsolateral dermomyotome. The ribs are formed through resegmentation of the sclerotomes with the beginning of the fifth embryological week. They begin growing from the thoracic vertebrae towards the ventral body wall where they fuse with the sternum 1 week later. The fusion of the ribs with the sternum occurs when the fusion of the two parallel sternal bands is completed. The chondral templates of the ribs ossify by endochondral ossification, beginning at the rib angle in the sixth week.

The sternum develops from a pair of lateral mesenchymal bands. The sternal bands move towards each other and fuse starting from the cranial end. There is evidence that the ribs develop independently from the sternum [33]. Interestingly, the sternal bands move together but not by the elongation of the ribs [33]. When the sternum bars attach together at the cranial endpoint, a single interclavicular blastema occurs which generates the manubrium and clavicle. At the end of the embryonic period, a chondral model of the manubrium sterni, the sternum itself and the processus xiphoideus are generated. The first ossification centre of the sternum appears at the sixth month and ossification is completed after the 12th year.

The development of the sternocostal joint is correlated with that of the sternum and the ribs [33]. The ribs come into contact wherever fusion of the sternum bands is completed. The presence of the sternal tissue band is a prerequisite for the formation of the ventral part of the rib (Fig. 2). However, until today, it is not clear whether mechanical stimulation, cell–cell interactions or messenger substances are principally responsible for the normal formation of the sternum. During development of the sternocostal articulation, scattered chondroblasts are involved [33]. The separation between the ribs and the sternum starts by the invasion of cells from the perichondrium between the ribs and the sternum. First, they produce layers of cells between the ribs and the sternum. Then, the cells in the middle layers orientate in a radial direction and form the basis for the sternocostal joints. It remains a matter of debate as to what extent the regulation of these processes is responsible for the pathophysiology of chest wall deformities. In this context, the analyses of the dynamic processes of ossification and cartilage maturation could open innovative perspectives.

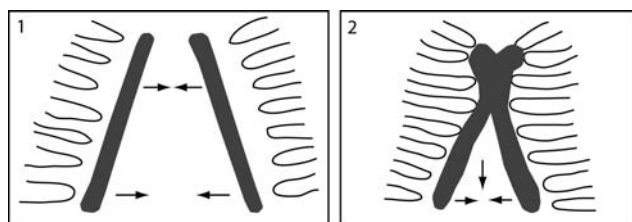


Figure 2: Schematic depiction of the embryological development of the sternum and the sterno-costal articulation via fusion of the sternal bands from cranial to caudal.

TREATMENT OF PECTUS EXCAVATUM

After the first documented surgical correction of PE by Meyer [9], Ravitch [34] performed a trend-setting open intervention technique in 1949. Six years later, Rehbein and Wernicke [35] used crossed metal blades during the operation to stabilize the chest wall.

The open approach of subperichondrial resection of all deformed costal cartilages, xiphoid resection and sternal osteotomy with anterior fixation of the sternum using mostly multiple bar implantation represented the gold standard up to the beginning of the last decade. The procedure consists of a median longitudinal incision along the sternum in males and a submammary skin incision in females, resection of the deformed costal cartilages and a complete mobilization of the sternum, usually requiring excessive retrosternal dissection and sternal transversal osteotomies. The final correction form of the ventral thorax aperture is fixed and stabilized using different metallic bar forms in a different number of implanted bars and their positioning, longitudinally and/or transversally, depending on the surgeon's preference. The operation time needed for the open correction ranges from 2 to 5 h and often a perioperative blood transfusion is necessary. Moreover, chest tubes and multiple wound drains are used in the majority of cases. Patient-controlled intravenous analgesia (PCA) or epidural catheter and/or opioid therapy for pain control are used most of the times. Patients are discharged from the hospital after 6–8 days on average. The implanted bars are removed 1 year after surgery during a short hospital stay of 2 to 3 days.

In 1998, Nuss *et al.* [36] introduced a minimally invasive technique as an alternative to the standard open repair, the so-called minimally invasive repair of pectus excavatum or minimal access repair of pectus excavatum. The Nuss procedure, which raises the sternum with a retrosternal metallic bar which is placed under thoracoscopic control, is based on the flexibility of the thorax in young subjects, making effective correction possible without the need for extensive costal cartilage resection or sternal osteotomy. The surgical procedure of the Nuss procedure consists of identifying the most depressed zone and the most everted costal line on the left and right side of the sternum, preparing the rectilinear metallic bar using flexible templates for the modulation of the bar length and curve shape. A slight overcorrection of the sternum is aimed for while the sternum is modulated. For this procedure, two skin incisions of 3–4 cm in length are made at the right and left middle axillary lines. Next, skin flaps are raised and tunnelled up to the predetermined points at the most-everted intercostals space. A thoracoscope is inserted between the two intercostal spaces below right thoracic incision for the visual control of instrumentation in the retrosternal space and to identify the deepest point of sternal depression. A metal introducer is entered intrathoracally at the predetermined points at the most everted intercostals space on the patient's right side facing forward, thus dissecting the plane separating the sternum from the pericardium. The guide is then exteriorized via the left side at the same level and then pushed through the skin incision. A tie is attached to the end of the introducer bar and the (trial bar) introducer is then removed backwards on the right side under thoracoscopic guidance, which allows the passage of the tie from left to right. The tie is then attached to the final bar, so that it can be inserted with the concave side facing forward from right to left, guided by the tie, while it is pulled up on the left. Under thoracoscopy, the retrosternal curve bar is rotated by

180° around its axis, so that the concave side faces backwards, thus pushing the sternum in ventral direction.

The bar is connected with one stabilizer on each side and attached to the lateral muscles of the chest wall. Some surgeons use one stabilizer on the right side only, but others additionally wire the bar to a rib with two or more subperiosteal cable wires. At the end of the procedure, the thoracic cavity is explored by the thoracoscope to ensure that there are no organic lesions or that the lung is trapped between the bar and the chest wall, and to evaluate possible bleeding. No systematic thoracic drainage or wound drains are left postoperatively, and the minor degree of pneumothorax often seen on postoperative plane chest X-ray has no consequences. The operative duration is 50 min on average and usually no ICU care is required. Pain control is managed in a manner identical to the description above and the length of hospital stay is usually 4–5 days. Previously, the bar was removed 2 years after surgery, although in the last years it is recommended to leave the bar *in situ* for 3 years. A modification for reducing severe complications such as cardiac perforation during Nuss procedure was established by Ohno *et al.* [37], who recommended, based on their experience, that the tip of the introducer has to be observed at all time under right and left thoracoscopic guidance.

Other operational techniques described in the literature for the correction of PE wall are the method of Leonard or Robicsek, which both represent modifications of the Ravitch operation. In the approach of the Leonard modification, a curvilinear incision is made over the sternum and after mobilization of the pectoral muscles the lower costal cartilage is removed, whereas the perichondrium is left in space. A wedge osteotomy is performed and instead of a bar there is a wire placed behind the sternum which is pulled up through separate stab incisions fixed to an external brace. The brace is worn for about 3 months [38].

During the method of Robicsek *et al.* [39], there is bilateral resection of the defective costal cartilages and a transverse wedge sternotomy. After mobilization of the sternum in the correct position, it is stabilized from behind through a Marlex mesh which is fixed to the cartilage remnants.

Different minimal invasive approaches are the so-called Erlangen technique and the magnetic mini-mover procedure: the operation with the 'Erlangen technique' is characterized by minimal resection of the cartilage and reduced anterolateral mobilization. The sternum is mobilized by retrosternal dissection via an anterior incision, and an elastic metal bar is implanted trans-sternally through stitch incisions. Minimal resection of a cartilage is provided by intraoperative tensiometry. This technique measures, at defined intervals, the necessary forces to elevate the chest wall and determines whether complete division is necessary. The metal bar will be removed after 1 year [40].

During the magnetic mini-mover procedure, a magnet is placed during this operational intervention upon the sternum. With a second magnet on a brace which must be worn by the patient, the magnetic force pulls the sternum out of its depressed position. The brace must be worn several months. In this operation, a metal plate is brought behind the sternum used as a counter-support for the magnet which will be placed on the sternum. Harrison *et al.* [41] reported that they were able to terminate this operation within 30 min. The operation needs general anaesthesia, but it is possible that patients can leave the hospital at the same day of surgical intervention. The detailed outcomes will be reported when Phase II of the clinical trial will be completed.

There is one surgical treatment of PE via sternochondroplasty introduced by Lacquet without the use of prosthetic material and with good long-term results [42]. In a recent survey, the sternochondroplasty is described to be superior to the Nuss procedure in the cases of asymmetric PE [43].

A non-surgical alternative in the treatment of PE represents the vacuum bell. Placed on the thorax, the patient produces a negative pressure with a handpump each day over several months. Schier *et al.* [44] demonstrated that the vacuum bell could be an alternative to the surgical treatment in less severe cases and in the preoperative preparation. Haecker [45] published 133 patients and confirmed the conclusions of Schier *et al.* [44]. However, long-term results are still lacking.

COMPARISON OF THE DIFFERENT SURGICAL INTERVENTIONS

Taking the different treatment options together, it becomes obvious that not all surgical methods are applicable for all manifestations of PE. In this context, Harrison *et al.* [41] demonstrated that an asymmetry of the sternum poses significant problems for the magnetic mini-mover. According to Coelho *et al.* [43], the sternochondroplasty is predominant in comparison to the Nuss procedure in the cases of asymmetric PE. A recent meta-analysis of the experience of the Ravitch and the Nuss procedure identified no differences in overall complications and length of hospital stay between these procedures [46]. In this meta-analysis, the Ravitch procedure revealed lower rates of re-operation, postoperative haemothorax and pneumothorax than in the Nuss procedure. Also in terms of patient satisfaction, no differences could be found between the different surgical techniques [46]. In a further survey by Antonoff *et al.* [38], the comparison between Ravitch, Nuss and Leonard operation procedures clearly demonstrated the highest levels for length of hospitalization, fees, analgesic needs and complication rates within the Nuss group, whereas in the patients treated with the Leonard operation the lowest values in these parameters could be found. Regarding the health-related quality-of-life (HRQL) outcomes, no significant differences were found between the Nuss and Ravitch procedure [47].

Taking these data of different treatment options together, an early long-term follow-up by Lacquet *et al.* [48] revealed that the subjective physical improvement after operation could not be explained by changes in static lung volumes or in cardiorespiratory function at exercise, but should be due to other unexplained factors.

FUTURE PERSPECTIVES FOR THE CORRECTION OF PECTUS EXCAVATUM

Most PE operation techniques are based on a stabilizing metal material which has to be removed in a second intervention, a fact which implicates several complications. First of all, a second intervention has to be performed [49]. In addition, the metal devices can shift and migrate into neighbouring tissue [49]. Furthermore, the introduced material can also cause problems such as postoperative chronic pain [32, 50]. In this context, the so-called Strasbourg Thorax Osteosynthesis System (STRATOS®), using titanium implants, reduced the risks of material shifting and allergy [51]. With a view to new biomedical material developments, the

use of absorbable material is of interest, since a second intervention would not be necessary. Several approaches using absorbable material for the correction of chest wall deformities were performed [20, 50, 52, 53]. Torre *et al.* [53] described the use of stabilizers made of poly-L-lactic-polyglycolic polymer. However, Pilegaard and Licht [54] published unsatisfying results using this device: they found a higher complication rate of the absorbable stabilizers for the Nuss technique.

Luzzi *et al.* [20] retrospectively analysed the treatment of PE using a bioabsorbable mesh instead of a metallic device in the Robicsek technique after a 10-year experience. They highlighted a lower inflammatory reaction, avoiding complications of retrosternal device dislocation, the reduction of re-operations to remove the metal devices and reduced postoperative chest pain allowing an earlier mobilization of the patient [20]. Länsman *et al.* [50] used bioabsorbable plates for the correction of PE in children and also demonstrated good results in the surgical correction. In addition, Gürkök *et al.* [52] reported the use of a resorbable copolymer plaque stating the advantage of a single operation. However, by using biodegradable materials, problems such as mechanical instability or a relevant pH shift due to the degradation with consecutive relevant inflammatory response should be taken into account. In this context, long-term experiments analysing the biocompatibility and potential recurrence of PE by use of different materials are needed to obtain information about the optimal material. Furthermore, trials are needed to define in which cases biodegradable materials should be preferred and in which cases metals would be the better choice. In this context, the systematic analyses of the biomechanics and the various forces acting in the thoracic cage would be very helpful in further optimizing or developing new material approaches using either biodegradable or non-biodegradable materials or new shape-memory metal devices. New approaches like these could open innovative perspectives for the rational use of different biomaterials for the correction of chest wall deformities.

Conflict of interest: none declared.

REFERENCES

- [1] Bauhinus J. Observatio. In: Ioannis Schenckii a Grafenberg, ed. Johannes Observatorium medicarum, rararum, novarum, admirabilium, et monstrarum, liber secundus. Frankfurt: De partibus vitalibus, thorace contentis, 1609, 322.
- [2] Woillez. Sur un cas de déformité thoracique considérable avec déplacement inoffensif de plusieurs organes et signes stéthoscopiques particulières. Paris: Rap Soc Med d'Hop, 1860, 3.
- [3] von Luschka H. Die Anatomie des Menschen in Rücksicht auf die Bedürfnisse der praktischen Heilkunde. Die Anatomie der Brust des Menschen. Tübingen: Laupp, 1863, 23.
- [4] Eggel. Eine seltene Mißbildung des Thorax. Virchows Arch Path Anat 1870;49:230.
- [5] Williams CT. Congenital malformation of the thorax great depression of the sternum. Trans Path Soc 1872;24:50.
- [6] Flesch M. Über eine seltene Missbildung des Thorax. Virchows Arch Path Anat 1873;75:289.
- [7] Hagmann. Selten vorkommende Abnormität des Brustkastens. Jb Kinderheilkunde 1888;15:455.
- [8] Langer E. Zuckerkandel: Untersuchungen über den mißbildeten Brustkorb des Herrn JW Wiener med Zeit 1880;49:515.
- [9] Meyer L. Zur chirurgischen Behandlung der angeborenen Trichterbrust. Berl Klin Wschr 1911;48:1563-66.
- [10] Kelly RE Jr, Lawson ML, Paidas CN, Hruban RH. Pectus excavatum in a 112-year autopsy series: anatomic findings and the effect on survival. J Pediatr Surg 2005;40:1275-8.
- [11] Ravitch MM. Repair of pectus excavatum in children under 3 years of age: a twelve-year experience. Ann Thorac Surg 1977;23:301.
- [12] Kelly RE Jr, Shamberger RC, Mellins RB, Mitchell KK, Lawson ML, Oldham K *et al.* Prospective multicenter study of surgical correction of pectus excavatum: design, perioperative complications, pain, and baseline pulmonary function facilitated by internet-based data collection. J Am Coll Surg 2007;205:205-16.
- [13] Fonkalsrud EW, Dunn JC, Atkinson JB. Repair of pectus excavatum deformities: 30 years of experience with 375 patients. Ann Surg 2000;231:443-8.
- [14] Kotzot D, Schwabegger AH. Etiology of chest wall deformities—a genetic review for the treating physician. J Pediatr Surg 2009;44:2004-11.
- [15] Colombani PM. Preoperative assessment of chest wall deformities. Semin Thorac Cardiovasc Surg 2009;21:58-63.
- [16] Beiser GD, Epstein SE, Stampfer M, Goldstein RE, Noland SP, Levitsky S. Impairment of cardiac function in patients with pectus excavatum, with improvement after operative correction. N Engl J Med 1972;287:267-72.
- [17] Kubiak R, Habelt S, Hammer J, Hacker FM, Mayr J, Bielek J. Pulmonary function following completion of Minimally Invasive Repair for Pectus Excavatum (MIRPE). Eur J Pediatr Surg 2007;17:255-60.
- [18] Malek MH, Berger DE, Housh TJ, Marelich WD, Coburn JW, Beck TW. Cardiovascular function following surgical repair of pectus excavatum: a metaanalysis. Chest 2006;130:506-16.
- [19] Coln E, Carrasco J, Coln D. Demonstrating relief of cardiac compression with the Nuss minimally invasive repair for pectus excavatum. J Pediatr Surg 2006;41:683-6; discussion 683-6.
- [20] Luzzi L, Voltolini L, Zacharias J, Campione A, Ghiribelli C, Di Bisceglie M *et al.* Ten year experience of bioabsorbable mesh support in pectus excavatum repair. Br J Plast Surg 2004;57:733-40.
- [21] Malek MH, Berger DE, Marelich WD, Coburn JW, Beck TW, Housh TJ. Pulmonary function following surgical repair of pectus excavatum: a meta-analysis. Eur J Cardiothorac Surg 2006;30:637-43.
- [22] Guntheroth WG, Spiers PS. Cardiac function before and after surgery for pectus excavatum. Am J Cardiol 2007;99:1762-4.
- [23] Johnson JN, Hartman TK, Pianosi PT, Driscoll DJ. Cardiorespiratory function after operation for pectus excavatum. J Pediatr 2008;153:359-64.
- [24] Aronson DC, Bosgraaf RP, Merz EM, van Steenwijk RP, van Aalderen WMvan Baren R. Lung function after the minimal invasive pectus excavatum repair (Nuss procedure). World J Surg 2007;31:1518-22.
- [25] Kelly RE Jr, Cash TF, Shamberger RC, Mitchell KK, Mellins RB, Lawson ML *et al.* Surgical repair of pectus excavatum markedly improves body image and perceived ability for physical activity: multicenter study. Pediatrics 2008;122:1218-22.
- [26] Brown AL. Pectus excavatum (funnel chest). J Thorac Surg 1939;9:164-184.
- [27] Sweet RH. Pectus excavatum: report of two cases successfully operated upon. Ann Surg 1944;119:922-34.
- [28] Fokin AA, Robicsek F, Watts LT. Genetic analysis of connective tissue in patients with congenital thoracic abnormalities. Interact CardioVasc Thorac Surg 2008;7:56.
- [29] Nakaoka T, Uemura S, Yano T, Nakagawa Y, Tanimoto T, Suehiro S. Does overgrowth of costal cartilage cause pectus excavatum? A study on the lengths of ribs and costal cartilages in asymmetric patients. J Pediatr Surg 2009;44:1333-6.
- [30] Geisbe H, Buddecke E, Flach A, Muller G, Stein U. 88. Biochemical, morphological and physical as well as animal experimental studies on the pathogenesis of funnel chest. Langenbecks Arch Chir 1967;319:536-41.
- [31] Rupperecht H, Hummer HP, Stoss H, Waldherr T. Pathogenesis of chest wall abnormalities—electron microscopy studies and trace element analysis of rib cartilage. Z Kinderchir 1987;42:228-9.
- [32] Feng J, Hu T, Liu W, Zhang S, Tang Y, Chen R *et al.* The biomechanical, morphologic, and histochemical properties of the costal cartilages in children with pectus excavatum. J Pediatr Surg 2001;36:1770-6.
- [33] Chen JM. Studies on the morphogenesis of the mouse sternum. II. Experiments on the origin of the sternum and its capacity for self-differentiation in vitro. J Anat 1952;86:387-401.
- [34] Ravitch MM. The operative treatment of pectus excavatum. Ann Surg 1949;129:429-44.
- [35] Rehbein F, Wernicke HH. The operative treatment of the funnel chest. Arch Dis Child 1957;32:5-8.
- [36] Nuss D, Kelly RE Jr, Croitoru DP, Katz ME. A 10-year review of a minimally invasive technique for the correction of pectus excavatum. J Pediatr Surg 1998;33:545-52.
- [37] Ohno K, Nakamura T, Azuma T, Yamada H, Hayashi H, Masahata K. Modification of the Nuss procedure for pectus excavatum to prevent cardiac perforation. J Pediatr Surg 2009;44:2426-30.

- [38] Antonoff MB, Erickson AE, Hess DJ, Acton RD, Saltzman DA. When patients choose: comparison of Nuss, Ravitch, and Leonard procedures for primary repair of pectus excavatum. *J Pediatr Surg* 2009;44:1113-8; discussion 118-9.
- [39] Robicsek F, Watts LT, Fokin AA. Surgical repair of pectus excavatum and carinatum. *Semin Thorac Cardiovasc Surg* 2009;21:64-75.
- [40] Weber PG, Huemmer HP, Reingruber B. Forces to be overcome in correction of pectus excavatum. *J Thorac Cardiovasc Surg* 2006;132:1369-73.
- [41] Harrison MR, Estefan-Ventura D, Fechter R, Moran AM Jr, Christensen D. Magnetic mini-mover procedure for pectus excavatum: I. Development, design, and simulations for feasibility and safety. *J Pediatr Surg* 2007;42:81-5; discussion 85-6.
- [42] Lacquet LK. Surgical treatment of anterior chest wall deformities by sternochondroplasty and internal fixation without prosthesis. *Acta Chir Belg* 1982;82:541-9.
- [43] Coelho Mde S, Silva RF, Bergonse Neto N, Stori Wde S Jr, dos Santos AF, Mendes RG *et al.* Pectus excavatum surgery: sternochondroplasty versus Nuss procedure. *Ann Thorac Surg* 2009;88:1773-9.
- [44] Schier F, Bahr M, Klobe E. The vacuum chest wall lifter: an innovative, nonsurgical addition to the management of pectus excavatum. *J Pediatr Surg* 2005;40:496-500.
- [45] Haecker FM. The vacuum bell for conservative treatment of pectus excavatum: the Basle experience. *Pediatr Surg Int* 2011;27:623-7.
- [46] Nasr A, Fecteau A, Wales PW. Comparison of the Nuss and the Ravitch procedure for pectus excavatum repair: a meta-analysis. *J Pediatr Surg* 2010;45:880-6.
- [47] Lam MW, Klassen AF, Montgomery CJ, LeBlanc JG, Skarsgard ED. Quality-of-life outcomes after surgical correction of pectus excavatum: a comparison of the Ravitch and Nuss procedures. *J Pediatr Surg* 2008;43:819-25.
- [48] Lacquet LK, Morshuis WJ, Folgering HT. Long-term results after correction of anterior chest wall deformities. *J Cardiovasc Surg (Torino)* 1998;39:683-8.
- [49] Stefani A, Morandi U, Lodi R. Migration of pectus excavatum correction metal support into the abdomen. *Eur J Cardiothorac Surg* 1998;14:434-6.
- [50] Lämsman S, Serlo W, Linna O, Pohjonen T, Törmälä P, Waris T *et al.* Treatment of pectus excavatum with bioabsorbable polylactide plates: preliminary results. *J Pediatr Surg* 2002;37:1281-6.
- [51] Wihlm JM, Grosdidier G, Chapelier A. Thoracic osteosyntheses for chest wall malformations, traumas and tumors using the STRATOS™ titanium system. *Interact CardioVasc Thorac Surg* 2007;6:273.
- [52] Gürkök S, Genc O, Dakak M, Balkanlı K. The use of absorbable material in correction of pectus deformities. *Eur J Cardiothorac Surg* 2001;19:711-2.
- [53] Torre M, Jasonni V, Asquasciati C, Costanzo S, Romanini MV, Varela P. Absorbable stabilisation of the bar in minimally invasive repair of pectus excavatum. *Eur J Pediatr Surg* 2008;18:407-9.
- [54] Pilegaard HK, Licht PB. Can absorbable stabilizers be used routinely in the Nuss procedure? *Eur J Cardiothorac Surg* 2009;35:561-4.

eComment. Pectus excavatum: the surgical opinion

Authors: Georgios Dimitrakakis and Ulrich O. von Oppell

Department of Cardiothoracic Surgery, University Hospital of Wales, Cardiff, UK
doi:10.1093/icvts/ivs186

© The Author 2012. Published by Oxford University Press on behalf of the European Association for Cardio-Thoracic Surgery. All rights reserved.

We read with great interest the state-of-the-art article by Brochhausen *et al.* regarding the pectus excavatum and we agree with the authors that its surgical treatment by various techniques can improve long term results in terms of cosmetics and potential cardiorespiratory function [1, 2]. Therefore, we would like to comment on the surgical approach.

Criteria for the surgical treatment of pectus excavatum, according to Kelly and colleagues, are related to the severity of symptoms and anatomical deformity followed by two or more criteria such as computerized tomography-index (or Haller-index) greater than 3.25, signs of cardiac and/or pulmonary compression on computerized tomography or echocardiography, mitral valve prolapse, arrhythmias and restrictive lung disease [2].

The minimally invasive Nuss procedure is safe [3]. In the relatively recent (study period 1987-2006) review of 18 series, reporting on 1949 children with a mean age of 10.6 years, there was no mortality and the incidence of morbidity was 15.4%. The average operative time was 68 minutes (from 28 to 200 min) and the average hospitalization was 5.5 days (from 2 to 27 days) [3]. The most common reported complications were bar related events (5.7%), pneumothorax (3.5%), wound infections (2.2%) and pleuropulmonary complications (2%) such as pleural effusions, atelectasis, and pneumonia [3].

In addition to common complications, Swanson and Colombani have reported on three cases within a period of 1 year with reactive pectus carinatum in patients who underwent pectus excavatum repair (two patients underwent minimally invasive Nuss procedure and one patient the Ravitch procedure). It should be noted that the pectus carinatum resolved in one patient who had an early bar removal. The other two patients required surgical correction at 3 and 6 years after the first surgical intervention. The need for close follow up for the early identification and successful treatment of this complication, particularly in the first six postoperative months, is of paramount importance [4]. In addition, Willekes *et al.* in their retrospective study of a 26-year experience with pectus deformities repair in 120 children with a mean age of 8.4 years (from 3 to 21 years) found that the long-term results of pectus deformities repair (excavatum and carinatum) through a vertical midline approach are excellent and the outcome with a temporary sternal bar is superior to that without a bar ($p = 0.004$). Nine patients had an associated congenital heart defect and underwent successfully simultaneous pectus excavatum and intracardiac repair with no additional morbidity [5].

In conclusion, surgical repair of pectus excavatum by various techniques has good long term results. However, a multidisciplinary approach and assessment of these patients on an individual basis is very important when considering the timing and type of procedure. A combined simultaneous approach in dealing with concomitant congenital or acquired heart conditions can be performed safely by an experienced team [2, 5].

References

- [1] Brochhausen C, Turial S, Müller FKP, Schmitt VH, Coerdts W, Wihlm JM, Schier F, Kirkpatrick CJ. Pectus excavatum: history, hypotheses and treatment options. *Interact CardioVasc Thorac Surg* 2012;14:801-806.
- [2] Kelly RE, Goretsky MJ, Obermeyer R, Kuhn MA, Redlinger R, Haney TS, Moskowitz A, Nuss D. Twenty-one years of experience with minimally invasive repair of pectus excavatum by the Nuss procedure in 1215 patients. *Ann Surg* 2010;252:1072-81.
- [3] Protopapas AD, Athanasiou T. Peri-operative data on the Nuss procedure in children with pectus excavatum: independent survey of the first 20 years' data. *J Cardiothorac Surg* 2008;3:40.
- [4] Swanson JW, Colombani PM. Reactive pectus carinatum in patients treated for pectus excavatum. *J Pediatr Surg* 2008;43:1468-73.
- [5] Willekes CL, Backer CL, Mavroudis C. A 26-year review of pectus deformity repairs, including simultaneous intracardiac repair. *Ann Thorac Surg* 1999;67:511-8.